

Hyperbaric Oxygen Therapy for the Compromised Graft or Flap

Ashish Francis and Richard C. Baynosa*

Division of Plastic Surgery, University of Nevada School of Medicine, Las Vegas, Nevada.

Significance: Tissue grafts and flaps are used to reconstruct wounds from trauma, chronic disease, tumor extirpation, burns, and infection. Despite careful surgical planning and execution, reconstructive failure can occur due to poor wound beds, radiation, random flap necrosis, vascular insufficiency, or ischemia–reperfusion (IR). Traumatic avulsions and amputated composite tissues—compromised tissue—may fail from crush injury and excessively large sizes. While never intended, these complications result in tissue loss, additional surgery, accrued costs, and negative psychosocial patient effects.

Recent Advances: Hyperbaric oxygen (HBO) has demonstrated utility in the salvage of compromised grafts/flaps. It can increase the likelihood and effective size of composite graft survival, improve skin graft outcomes, and enhance flap survival. Mechanisms underlying these beneficial effects include increased oxygenation, improved fibroblast function, neovascularization, and amelioration of IR injury.

Critical Issues: Common strategies for the compromised graft or flap include local wound care, surgical debridement, and repeated reconstruction. These modalities are associated with added costs, time, need for reoperation, morbidity, and psychosocial effects. Preservation of the amputated/avulsed tissues minimizes morbidity and maximizes the reconstructive outcome by salvaging the compromised tissue and obviating additional surgery. HBO is often overlooked as a potential tool that can limit these issues.

Future Directions: Animal studies demonstrate a benefit of HBO in the treatment of compromised tissues. Clinical studies support these findings, but are limited to case reports and series. Further research is needed to provide multicenter prospective clinical studies and cost analyses comparing HBO to other adjunctive therapies in the treatment of compromised grafts/flaps.

Keywords: hyperbaric, graft, flap, compromise, hypoxia



Richard C. Baynosa, MD, FACS

Submitted for publication September 3, 2016.
Accepted November 4, 2016.

*Correspondence: Division of Plastic Surgery,
University of Nevada School of Medicine, 1701
West Charleston Blvd., Suite 490, Las Vegas, NV
89102 (e-mail: rbaynosa@medicine.nevada.edu).

SCOPE AND SIGNIFICANCE

GRAFTS AND FLAPS are common reconstructive procedures used for the definitive management of surgical wounds. There is no role for hyperbaric oxygen (HBO) therapy in healthy, uncompromised skin grafts, composite grafts, or flaps. The ideal treatment for graft/flap compromise is prevention by recognizing poorly perfused wound beds that may lead

to compromise of the transferred tissue. Many of these wounds can be preemptively treated with HBO therapy for the respective problem wound indications to minimize the chance of compromise and improve the chance of reconstructive success. Certain situations such as radiation damage, low wound bed oxygen tension, vascular insufficiency, random-pattern flap ischemia, and

ischemia–reperfusion (IR) injury, however, may be unrecognized or unavoidable and can result in graft or flap compromise. HBO, in these cases, represents a valuable, even critical, salvage option. This review will highlight the animal studies and clinical evidence regarding HBO following flap and graft compromise.

TRANSLATIONAL RELEVANCE

The experimental evidence regarding HBO on skin grafts, flaps, and radiation injury will be reviewed. As will be discussed, studies have demonstrated that HBO improves wound oxygen tension, improves collagen synthesis and fibroblast function, improves vascularization, enhances flap circulation, and mitigates the deleterious effects of IR injury. Animal studies have proven that this treatment modality improves wound healing, as well as graft/flap viability. The final common pathway that mediates these favorable outcomes is the reversal of tissue hypoxia.

CLINICAL RELEVANCE

Current treatment strategies for compromised grafts and flaps include local wound care, vacuum-assisted closure, surgical debridement, and additional reconstructive procedures. These are associated with increases in healthcare-associated costs and patient discomfort, and may lead to additional donor site morbidity and negative effects on patient well-being. HBO has an important and beneficial role in treating these conditions. This review will highlight the clinical studies demonstrating tissue graft and flap salvage following HBO.

BACKGROUND/OVERVIEW

As one area of a broad clinical specialty, reconstructive surgeons are frequently called upon to treat a variety of surgically created and/or chronic nonhealing wounds. The etiologies of these wounds can include trauma, chronic disease, tumor extirpation, and burns. Furthermore, these wounds can be associated with radiation injury, chronic disease, infection, or inherent poor vascularity. It is therefore imperative that the surgeon's armamentarium be equipped with techniques that can address these complex situations.

The “reconstructive ladder” has classically been an algorithmic approach to wound treatment that begins with utilizing the simplest reconstructive techniques (*e.g.*, secondary intention and primary closure) and progresses in a stepwise manner to

more sophisticated techniques of wound closure (*e.g.*, free tissue transfer). Gottlieb and Krieger presented the concept of the “reconstructive elevator,” which permitted the initial selection of a more “complex” option in order to provide a wound closure tailored to the individual patient and wound characteristics.¹

Of the reconstructive options available to the reconstructive surgeon, grafts and flaps are the most common. Despite careful patient selection, preoperative planning, and operative technique, flap and graft failure can occur, potentially within the first 24–48 h. In addition, traumatic injuries such as dog bites commonly produce avulsions of composite tissues that effectively create compromised grafts or flaps as demonstrated in Fig. 1. HBO therapy is not indicated for the treatment of uncompromised wounds or grafts/flaps. It is indicated in cases of threatened grafts or flaps where hypoxia and impaired perfusion are present after transfer and inset of the tissues and have been proven to improve tissue viability.² Understanding the factors that threaten graft and flap viability is crucial to understanding the mechanisms through which HBO exerts its beneficial effects.

Grafts contain single or multiple tissue types (referred to as composite grafts) of varying size and depth that lack their own blood supply. The latter property makes these entities reliant upon their recipient bed for initial nutrient diffusion, revascularization, and ultimately, survival. This process of graft “take” follows a characteristic clinical progression, more noticeable in composite grafts. The

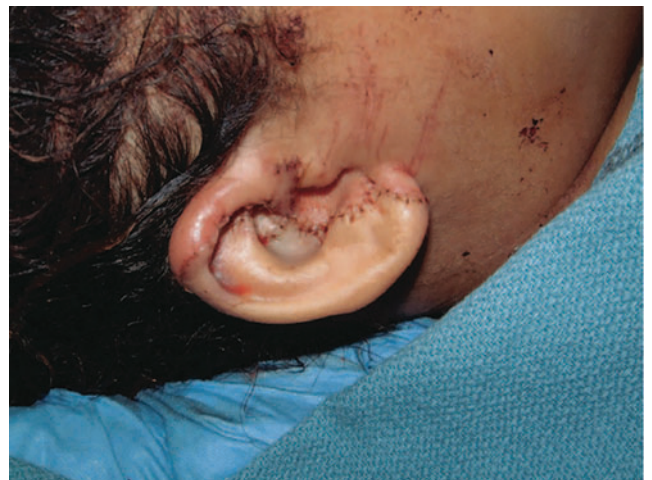

Figure 1. Reattachment of near-total ear amputation as a composite graft. This type of injury, resulting from a dog bite in this case, effectively produces a compromised graft due to large graft size and high metabolic demands due to the presence of multiple tissues. These limitations may be overcome by HBO. HBO, hyperbaric oxygen.

graft is initially pale and avascular, then adopts a bluish hue due to early congestion (as mature vascular connections have not developed as yet), and finally develops a progressive pink blush. As a consequence, factors that threaten the recipient bed also threaten graft viability. These factors are ideally identified and treated preoperatively. However, situations may arise in which a questionable wound bed or a graft with metabolic demand greater than the vascularization capacity of the recipient bed (*i.e.*, composite grafts) is encountered. Both of these situations are characterized by hypoxia. Graft compromise may be evident in the first 24–48 h, characterized by a dusky appearance, epidermolysis, and later, desiccation and necrosis (Fig. 2). HBO in these circumstances can improve the wound oxygen tension, local circulation, and angiogenesis and, thus, salvage the failing graft, obviating the necessity for debridement and re-grafting.

Flaps, on the other hand, are units of tissue that carry their own inherent blood supply from the donor to the recipient site. They are susceptible to their own unique sources of compromise. Random-pattern flaps can undergo ischemia usually occurring distally—the area furthest from the source of vascular perfusion—if the flap length exceeds its vascular capabilities. Pedicled flaps can experience mechanical obstruction to blood flow, including pedicle kinking or twisting. Free tissue transfer, in which a flap is divided and transferred to a distant recipient bed with microsurgical reanastomosis, is susceptible to IR injury. All flaps may be threat-

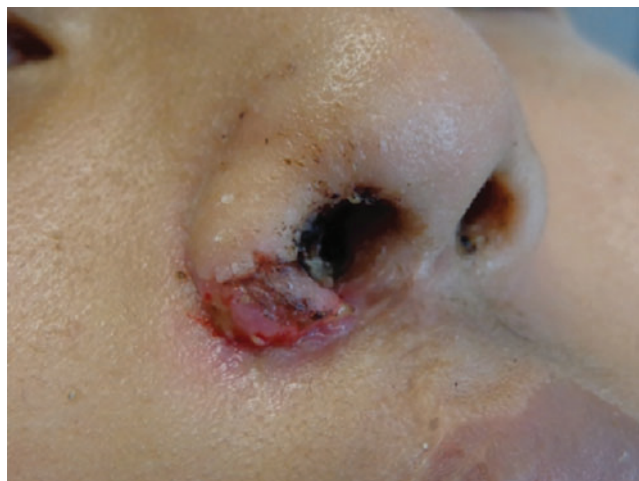

Figure 2. Composite graft failure following nasal reconstruction. Graft failure may be seen within 24–48 h. Clinically, threatened grafts may be characterized by a dusky appearance, epidermolysis, and ultimately necrosis. Prompt recognition is crucial.

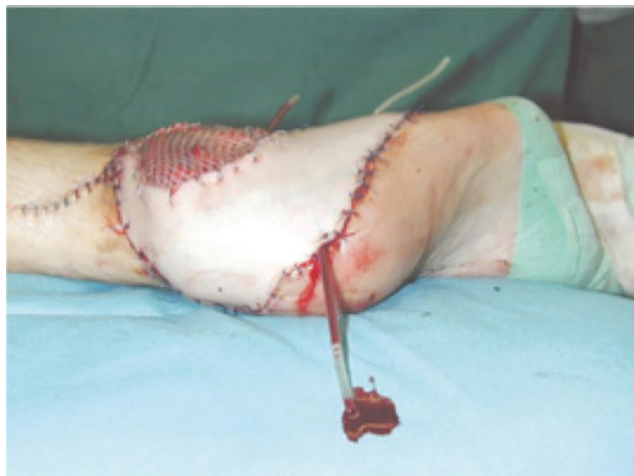

Figure 3. Arterial insufficiency of a lower extremity musculocutaneous flap. These flaps appear pale, demonstrate slow capillary refill, impaired turgor, are cool to touch, and have delayed bleeding with pinprick. Arterial flap failure may be due to: extrinsic factors, including pedicle twisting/kinking during transposition, pressure at the pedicle base, or pedicle compression from seroma and hematoma; or less commonly, intrinsic factors, such as arterial thrombosis during microvascular transfer.

ened by arterial insufficiency (Fig. 3), venous congestion (Fig. 4), and complete arterial or venous occlusion. Any surgically correctable etiology for flap compromise should be reversed as soon as it is discovered. HBO, however, can enhance flap survival when tissue damage persists despite no correctable etiology being found during surgical re-exploration.

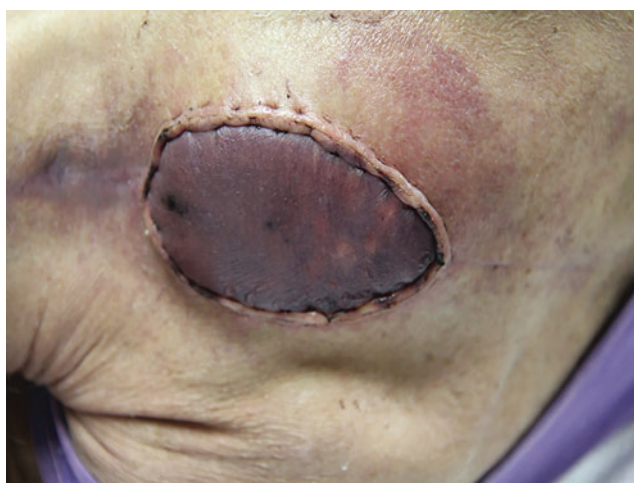

Figure 4. Venous congestion of a trunk musculocutaneous flap. These flaps appear blue to purple, demonstrate brisk capillary refill, increased turgor, are warm to palpation, and have dark prompt bleeding with pinprick. Venous congestion occurs more commonly than arterial insufficiency due to decreased vessel compliance and is the most common complication of microvascular transfer in the first 24 h.

DISCUSSION

Mechanisms of action

Hypoxia is the underlying factor in non-healing tissue and compromised grafts and flaps, with measured oxygen tension between 5 and 20 mmHg.³ Oxygen is required for fibroblast function and collagen synthesis, which in turn provide normal wound healing. HBO, typically administered at pressures of 2.0–2.5 atmospheres absolute (ATA) for periods of 90–120 min twice daily, allows complete hemoglobin saturation with oxygen in the circulation, as well as up to 10-fold increases in dissolved oxygen plasma levels. Plasmatic contributions to oxygenation, normally relatively minor, are increased by HBO to levels suitable to support tissue metabolism. This is exhibited by the oxygen content equation, where Hb is hemoglobin concentration, SaO₂ is oxygen saturation, and PaO₂ is the dissolved plasmatic oxygen concentration:

$$CaO_2 = 1.34 \times Hb \times SaO_2 + 0.003PaO_2$$

Given this dramatic increase, the oxygen diffusion gradient is greatly improved and favors delivery of oxygen from the plasma to the compromised tissues. Plasmatic imbibition, the initial stage of graft healing, is therefore enhanced. Early work by Sheffield measuring transcutaneous oxygen levels during HBO therapy demonstrated that normal tissue oxygenation is restored, thereby improving fibroblast activity and tissue healing.⁴ It is apparent that HBO provides a temporary stimulus for wound healing in this setting, but ultimately, maintenance of tissue oxygenation requires restoration of vascularity to the compromised tissue.

Improved vascularity has also been demonstrated following administration of HBO. Manson *et al.* demonstrated in a skin flap model that capillary proliferation is increased following HBO therapy.⁵ Similarly, Nemiroff demonstrated significant improvements in the quantity of capillaries in the microvasculature of skin flaps, as well as increased vessel surface area in the HBO groups compared to controls.⁶ More recently, HBO has been shown to improve wound angiogenesis by upregulating vascular endothelial growth factor (VEGF) transcription and translation.⁷ While the increase in tissue oxygenation is a short-term effect of HBO, increased VEGF production and the associated subsequent cellular interactions represent a long-term beneficial effect of HBO in ischemic tissue. VEGF has been shown to enhance nitric oxide (NO) synthesis by inducing expression of the endothelial cell isoform of nitric oxide synthase

(NOS).⁸ The well-documented vasodilatory effect of NO is likely another mechanism for the improved oxygen tension in compromised grafts and flaps treated with HBO.

IR injury refers to the tissue and microvasculature injury that is seen despite restoration of blood flow after an initial ischemic insult, often affecting free flaps. A distinct pattern of tissue damage is caused by IR injury, characterized by reactive oxygen species damage, microvascular vasoconstriction, and neutrophil adhesion/infiltration; this can be reversed or limited by HBO. The initial studies demonstrating the beneficial effect of HBO therapy on IR injury were performed by Zamboni *et al.*, using an axial skin flap model in rats. HBO unexpectedly demonstrated improved skin flap survival and perfusion confirmed by laser Doppler analysis.^{9,10} In a rat-free skin flap model, HBO also showed a three- to sixfold improvement in survival after microsurgical anastomosis.¹¹ Other animal studies have demonstrated upregulation of antioxidant systems following HBO therapy in the context of IR injury, as well as decreased oxygen radical-induced lipid peroxidation.^{12,13} Using rat pedicle skeletal muscle flaps, it was shown that neutrophil adhesion to endothelial cells through neutrophil beta-2-integrin CD18 surface molecule was also inhibited by HBO in a NO-dependent manner.^{14,15} Microvascular vasoconstriction was also reversed following HBO. Conversely, it is well known that HBO induces vasoconstriction. This effect on graft and flap survival might seem counterintuitive. However, vasoconstriction allows inhibition of edema and overall improvement in blood flow.¹⁶ Furthermore, Reinisch presented evidence supporting the theory that flap failure may result from distal flap arteriovenous shunt development.¹⁷ Selective vasoconstriction of these shunts in viable areas following HBO may improve circulation in compromised ischemic areas.

Through these studies it is evident that HBO improves flap and graft survival by increasing oxygen tension, upregulating fibroblast activity and collagen synthesis, enhancing angiogenesis, and altering flap circulatory dynamics to increase blood flow and decrease edema.

Animal studies

A number of animal studies have been undertaken that examine wound healing in questionable recipient beds, compromised graft healing, composite graft survival, and threatened flap viability. Compromised wound beds are unfavorable for skin/composite grafts and inhibit wound healing and epithelialization. Kivisaari and Niinikoski

demonstrated that HBO at 2.0 ATA resulted in improved wound closure of compromised wounds created by devascularizing the wound edges. No effect was observed in vascularly intact wounds.¹⁸ Korn *et al.* found improved epithelialization rates compared to controls following HBO treatment of second degree burns in guinea pigs.¹⁹ Similar improvements in healing time were noted by Shulman and Krohn in full- and partial-thickness wounds in rats. They also noted that repeat skin grafting and HBO resulted in a 50% improvement in healing time of partial-thickness wounds.²⁰

Animal studies examining the effect of HBO on compromised tissue grafts are plentiful. A study of HBO on rabbit epiphyseal growth cartilage transplantation demonstrated histologic evidence of successful transplantation in 50% of the HBO-treated rabbits compared to 28% in the control group.²¹ Other studies of rabbit auricular composite chondrocutaneous grafts have shown an overall survival benefit following HBO therapy.^{22,23} Zhang *et al.*, focused more specifically on the survival area of rat composite skin grafts. They found that HBO administered at 2.0 ATA daily for 5 days increased graft survival area by 82% compared to 26.5% in nontreated controls.²⁴

It should be noted that these studies all examined grafts measuring 2.0 cm, while 1.5 cm has largely been recognized as the upper size limit to ensure successful composite graft take. Larger sizes exceed the metabolic and oxygen capacity provided by the wound bed. These larger size composite grafts are rare in elective clinical situations, but are commonly seen in traumatic avulsion injuries and dog bites. In general, the limiting factor in graft survival is the metabolic requirement of the graft (composite or otherwise) in comparison to the oxygenation available by plasmatic imbibition from the underlying wound bed. As discussed previously, HBO treatments can increase the amount of dissolved oxygen within plasma tenfold, allowing sufficient oxygenation to meet increased metabolic demands for larger grafts. To address size constraints of chondrocutaneous composite grafts, Li *et al.* utilized a rabbit ear model and compared sizes of 0.5, 1.0, and 2.0 cm in diameter. HBO was provided for 90 min at 2.4 ATA for 5 days. At 3 weeks, the 2.0-cm group treated with HBO had nearly a 35% increase in survival versus controls. Interestingly, HBO did not provide a survival benefit for the smaller grafts.²⁵ As a result, HBO may increase the likelihood of survival for larger composite grafts that may arise in the traumatic setting as opposed to the carefully planned reconstructive setting.

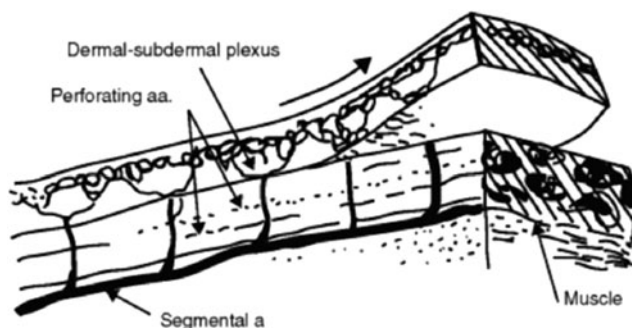


Figure 5. Anatomy of random-pattern flaps. These flaps are dependent on the local circulation of the subdermal plexus and are more susceptible to distal ischemia. Reprinted by permission from Zamboni *et al.*

Random-pattern flaps, as shown in Fig. 5, are based on the subdermal plexus and are limited to a 2:1 to 3:1 length-to-width ratio.²⁶ These flaps are perhaps the most susceptible to ischemia and compromise even in light of careful surgical planning. A randomized controlled study in rats performed by Nemiroff *et al.* studied random skin flap survival following HBO therapy. Groups receiving HBO therapy within 4 h of flap elevation had a 22% increase in flap survival.²⁷ In addition, Arturson and Khanna designed a dorsal random skin flap that produced consistent necrosis upon elevation. Subjecting these flaps to HBO and other flap-enhancing agents demonstrated that HBO significantly improved flap survival over controls and to a greater extent than other agents.²⁸ Similar results have been demonstrated in pig models of random flaps: treatment with HBO for 90 min at 2.0 ATA produced a decrease in flap necrosis of 35%.²⁹

In contrast to random flaps, axial or pedicle flaps contain a direct source artery providing the vascular supply (Fig. 6).²⁶ Studies on pedicle flaps have confirmed the benefit of HBO therapy. Champion *et al.* demonstrated 100% survival of pedicle flaps in a rabbit model treated with HBO at 2.0 ATA for 2 h twice daily for 5 days compared to

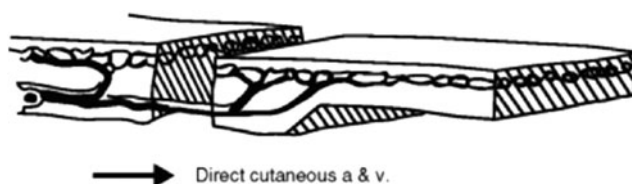


Figure 6. Anatomy of axial or pedicle flaps. This cutaneous flap has its own defined vascular territory supplied by a single source artery and vein. Pedicle flaps may contain various tissue types, including fascia, muscle, or bone. Compared to random flaps, their blood supply is more robust. Reprinted by permission from Zamboni *et al.*

untreated flaps that showed 40% necrosis.³⁰ Jurell and Kaijser showed a twofold increase in flap survival area compared to controls after HBO therapy in a rat model. Although there was an improvement in survival area if HBO was delayed for 24 h, viability was greater when initiated immediately after surgery. This finding highlights the crucial point that HBO therapy is time dependent with respect to flap salvage and should be started as soon as flap compromise is observed.³¹ Other studies have been performed to elucidate the role of HBO in pedicle flaps suffering from vascular insufficiency. Venous congestion due to venous thrombosis following microsurgical anastomosis is the most common early complication following free tissue transfer; it may also occur in pedicle flaps if there is mechanical occlusion. A study by Lozano *et al.*, compared HBO therapy and leech therapy in skin flaps that experienced venous occlusion. Venous occlusion resulted in 100% flap necrosis; HBO therapy resulted in 1% survival; leeching resulted in 25% survival; and HBO and leeching combined resulted in 67% survival.³² These findings demonstrate that HBO may improve flap salvage rates when combined with medicinal leeching in cases of venous congestion. Ulkur *et al.* examined arterial, venous, and arteriovenous insufficiency compromise of pedicle flaps and showed that HBO improved flap survival length and Doppler flow in all cases, with arterial insufficiency showing the greatest improvement.³³

As can be seen, different animal models were utilized to compare tissues of varying blood supply (*i.e.*, grafts, pedicle flaps, random-pattern flaps, and free flaps). Tissue compromise was established by several different mechanisms; however, the final outcome ultimately centered upon graft/flap hypoxia. The experimental studies outlined in this study provided evidence that HBO is beneficial in improving wound healing and graft/flap viability by diminishing tissue hypoxia, likely through the mechanisms outlined previously.

Clinical studies

Given the success of HBO therapy in experimental studies for the treatment of compromised graft and flap survival, multiple studies have been undertaken to see if this effect translates to the clinical setting. Perrins and Cantab conducted a prospective, randomized controlled clinical study that looked at the influence of HBO therapy on split-thickness skin grafting providing Level I evidence of the efficacy of HBO. The authors found a 29% increased survival of skin graft surface area. Moreover, complete skin graft take (considered

>95% of surviving graft area) was noted in 64% of HBO-treated cases compared to 17% of untreated controls.³⁴ In addition, 100% of HBO therapy patients achieved greater than 60% graft take compared to 64% of controls. Although the etiology of graft compromise in this study is not defined, the patients in this study clearly manifest an etiology for graft compromise seen by the low success rates in the control population. In addition, skin graft thickness was not controlled and the authors note particularly impressive successful take with the thick skin grafts.

Further review of the literature demonstrates a paucity of evidence regarding the use of HBO for the treatment of compromised skin grafts. This is likely due to our increased knowledge of the importance of wound bed preparation and factors that can influence the viability of the underlying wound bed, including soft tissue radiation damage, bacterial contamination, peripheral vascular disease for extremity wounds, and chronic steroid use. In addition, the instruments for harvesting split-thickness skin grafts allow for increased precision with the depth of harvest of skin grafts that was not previously available. In general, clinicians are now extremely astute in diagnosing the suitability of the wound bed for split-thickness skin grafting and HBO would not be indicated in any routine skin grafting procedure. More appropriately, HBO may be beneficial in preparing certain wounds (*e.g.*, radiation-damaged or diabetic wounds) by improving the underlying vascularity to permit healing of a skin graft, but further discussion of this indication is beyond the scope of this review.

Case reports are plentiful outlining the beneficial effects of HBO in the salvage of composite grafts. Nichter *et al.* outlined a successful composite graft nose replantation following HBO after near-total amputation after a dog bite.³⁵ Given the lack of appropriate recipient vessels for microsurgical replantation and having graft dimensions exceeding the 1.5–2.0 cm limit for composite grafts, HBO was sought as an adjunctive therapy to salvage the graft. While the survival of the replanted nose cannot be attributed solely to HBO, the authors noted a change in graft appearance from white to pink during its administration, implying a role in the graft's survival. Another case report documented immediate reconstruction of a traumatic nasal defect using an auricular composite graft with adjunctive HBO, obviating the need for a paramedian forehead flap reconstruction and its disfiguring donor site defect.³⁶ It is worth noting that these and other cases of successful composite grafting are predominantly seen in the pediatric

population, perhaps due to their lack of comorbidities and higher angiogenesis capability.³⁷

Bowersox *et al.*, examined ischemic grafts or flaps in 105 patients, in which 90% had factors associated with poor graft or flap survival. In this study, ~90% of compromised grafts and flaps were salvaged with HBO.³⁸ In a retrospective study of free flaps and replantations, the authors found a positive correlation between flap/replant survival and early HBO therapy, noting 100% graft loss when HBO was started after 3 days.³⁹ This clinical study again echoes the importance of prompt HBO administration when tissue compromise is suspected. A retrospective, controlled cohort study by Roje *et al.* was performed on 388 patients, evaluating the effect of HBO on short-term complications for war injury reconstructions. Skin graft loss was significantly higher in controls versus the HBO-treated group (52% vs. 23%, respectively). Flap necrosis was also significantly higher in the controls compared to the HBO-treated group (51% vs. 15%, respectively).⁴⁰

More recently, Larson *et al.* conducted a retrospective review of patients receiving HBO, with 15 being treated for compromised postreconstructive flaps. Eleven patients demonstrated flap salvage: seven showed an improvement and four demonstrated complete healing. The authors noted that patient compliance and high pretreatment oxygen tension were associated with a favorable outcome.⁴¹ Another recent retrospective review demonstrated 75.7% successful salvage of failed flaps or skin grafts following an average of 30 HBO treatments.⁴² Qing *et al.*, retrospectively examined four patients undergoing auricular composite graft nasal tip reconstruction with HBO initiated immediately postoperatively. All patients went on to have successful healing.⁴³

A case report of a patient with radiation damage undergoing mastectomies with tissue expander reconstruction documented intraoperative ischemia. Subsequently, HBO therapy was initiated immediately and continued until the third postoperative day. The mastectomy skin flaps at that time showed marked improvement and the patient was able to complete her breast reconstruction.⁴⁴ A 2016 case report was provided by Copeland-Halperin *et al.*, in which a patient with a history of radiation suffered mastectomy skin flap ischemia during nipple-sparing mastectomies and immediate reconstruction with tissue expanders. Prompt HBO therapy for 15 treatments resulted in complete flap salvage and successful completion of the reconstruction.⁴⁵ To date, the largest review of randomized controlled clinical studies on the use of HBO on flaps and grafts was performed by Zhou

et al. It encompassed 957 HBO patients and 583 control patients and included 23 total clinical trials (16 controlled trials and 12 randomized controlled trials). The results were overwhelmingly positive with a 62.5–100% survival rate in those treated with HBO compared to 35.0–86.5% in controls, especially if treatment was initiated within 72 h after surgery. However, HBO treatment in this study was planned rather than used as a salvage modality.⁴⁶ In addition, HBO therapy was performed at different times and regimens, and small sample sizes were noted in most of the studies.

Regarding HBO cost-effectiveness, data are limited, but Tibbles and Edelsberg pointed out that an average 90-min HBO treatment (generally recommended for problem wounds) costs between \$300 and \$400; over the course of the 30–40 sessions that are typically required, the overall cost is \$9,000–\$16,000.⁴⁷ In a study of patients with osteoradionecrosis, HBO and surgery demonstrated a savings of \$96,000 versus in-hospital non-HBO therapy.⁴⁸ This evidence suggests a cost benefit with HBO therapy for compromised wounds, but additional cost–utility analyses are required to confirm these findings.

Many of the studies above demonstrated variation in their HBO treatment protocols. Traditionally, this has been due to the variability in modalities that certain centers have for providing HBO treatment, which can be in either monoplace or multiplace chambers with or without air breaks to decrease the risk of oxygen toxicity. For the treatment of compromised grafts or flaps, our group has proposed that HBO be administered at 2.0–2.5 ATA from 90 to 120 min based on the recommendations of the Undersea and Hyperbaric Medical Society.^{2,49} Treatment is initiated upon recognition of graft/flap failure and after mechanical causes have been addressed appropriately, typically twice daily. Regular clinical assessments are performed to assess tissues for improved viability, vascularity, and stability and may be aided by adjuncts such as transcutaneous oximetry (TCOM) and laser Doppler studies. Once the flap/graft appears clinically viable and stable, treatments may be transitioned to once-a-day. TCOM measurements <40 mmHg suggest continued flap compromise and warrant continued therapy.⁵⁰ These measurements will typically increase during treatments and TCOMs can be recorded at pressure to document response or lack thereof. Twenty treatments are typically utilized, after which utilization review may be necessary.

The clinical studies outlined in this study support HBO therapy for grafts and flaps. Still, the

quality of the evidence is limited since the preponderance of data is largely in the form of case reports and series. Multi-center, randomized prospective clinical studies and cost-effectiveness analyses are needed to further study the efficacy of HBO in compromised grafts and flaps compared to other treatment modalities.

SUMMARY

HBO is not necessary for uncompromised grafts or flaps, but can be an invaluable adjunct for salvage once graft or flap compromise is recognized. It is vital to promptly diagnose flap or graft compromise using clinical judgment and correct any reversible mechanical causes surgically first. If no mechanical etiology is noted or tissue compromise persists, HBO administration should be performed expeditiously. HBO can salvage compromised grafts and flaps, as demonstrated by numerous animal and clinical studies. In doing so, additional healthcare costs, donor site morbidity, need for multiple surgical procedures, and negative patient psychosocial effects can potentially be avoided. The mechanisms behind the beneficial effect of HBO include increased dissolved plasmatic oxygen tension, enhanced fibroblast function and collagen synthesis, stimulation of angiogenesis, and alterations to local tissue circulation. Further investigation in the form of multicenter, randomized prospective clinical studies and economic analyses is needed to further study the efficacy of HBO in compromised grafts and flaps.

ACKNOWLEDGMENT AND FUNDING SOURCES

No financial support was provided for the preparation of this article.

AUTHOR DISCLOSURE AND GHOSTWRITING

No competing financial interests exist. The content of this article was expressly written by the

TAKE-HOME MESSAGES

- Grafts and flaps are common procedures to reconstruct surgical wounds.
- Compromised grafts and flaps can result in increased health care costs, additional patient discomfort, need for repeat surgical procedures, and negative patient well-being.
- HBO is not indicated for healthy noncompromised tissue, but is a valuable salvage adjunct in the treatment of threatened grafts and flaps.
- Mechanisms for HBO efficacy in compromised wounds include increasing wound oxygen levels, stimulating wound healing, and improving blood vessel growth and local circulation.
- Animal and clinical studies have demonstrated that HBO therapy improves graft and flap survival, limits tissue death, improves flap circulation, and can be combined with other treatment options to maximize tissue salvage.
- Clinical judgment is required to identify flap and graft compromise. Graft compromise, for which HBO may help, may be evident in the first 24–48 h, characterized by a dusky appearance, epidermolysis, and later, desiccation and necrosis. Flap compromise is characterized by arterial insufficiency (pale, delayed capillary refill, decreased turgor, and cool temperature), venous congestion (bluish-purple, brisk capillary refill, increased turgor, and warm temperature), or complete arterial/venous occlusion.
- Etiologies of graft or flap compromise that can be reversed surgically should be addressed first. If no mechanical cause is identified or tissue compromise persists, HBO should be administered expeditiously to maximize its therapeutic benefit.
- For compromised grafts or flaps, HBO should be administered at 2.0–2.5 ATA from 90 to 120 min twice daily initially and then transitioned to once-a-day treatments when clinical assessment and other adjuncts such as TCOM or laser Doppler demonstrate improved viability, vascularity, and tissue stability.

authors listed. No ghostwriters were used to write this article.

ABOUT THE AUTHORS

Ashish Francis, MD, is a resident physician in the Division of Plastic Surgery at the University of Nevada School of Medicine. **Richard C. Baynosa, MD, FACS**, is an Associate Professor and Chief of the Division of Plastic Surgery at the University of Nevada School of Medicine. He is also the current President of the Pacific Chapter of the Undersea and Hyperbaric Medical Society.

REFERENCES

1. Gottlieb LJ, Krieger LM. From the reconstructive ladder to the reconstructive elevator. *Plast Reconstr Surg* 1994;93:1503–1504.
2. Weaver L, ed. *Hyperbaric Oxygen Therapy Indications*, 13th ed. North Palm Beach, FL: Best Publishing Company, 2014.
3. Sheffield PJ. Tissue oxygen measurements. In: Davis JC, Hunt TK, eds. *Problem Wounds: The Role of Oxygen*. New York: Elsevier, 1988:17–51.
4. Sheffield PJ. Tissue oxygen measurements with respect to soft tissue wound healing with normobaric and hyperbaric oxygen. *HBO Rev* 1985;6:18–46.
5. Manson PN, Im MJ, Myers RA, Hoopes JE. Improved capillaries by hyperbaric oxygen in skin flaps. *Surg Forum* 1980;31:564–566.
6. Nemiroff PM, Lungu AP. The influence of hyperbaric oxygen and irradiation on vascularity in skin flaps: a controlled study. *Surg Forum* 1987;38:565–567.
7. Sheikh AY, Gibson JJ, Rollins MD, Hopf HW, Hussain Z, Hunt TK. Effect of hyperoxia on vascular endothelial growth factor levels in a wound model. *Arch Surg* 2000;135:1293–1297.
8. Hood JD, Meininger CJ, Ziche M, Granger HJ. VEGF upregulates eNOS message, protein, and NO production in human endothelial cells. *Am J Physiol* 1998;H1054–H1058.
9. Zamboni WA, Roth AC, Russell RC, Nemiroff PM, Casas L, Smoot EC. The effect of acute hyperbaric oxygen therapy on axial pattern skin flap survival when administered during and after total ischemia. *J Reconstr Micro* 1989;5:343.
10. Zamboni WA, Roth AC, Russell RC, Smoot EC. Effect of hyperbaric oxygen on reperfusion of ischemic axial skin flaps: a laser doppler analysis. *Ann Plast Surg* 1992;23:339.
11. Kaelin CM, Im MJ, Myers RA, Manson PN, Hoopes JE. The effects of hyperbaric oxygen on free flaps in rats. *Arch Surg* 1990;125:607–609.
12. Godman CA, Joshi R, Giardina C, Perdrizet G, Hightower LE. Hyperbaric oxygen treatment induces antioxidant gene expression. *Ann N Y Acad Sci* 2010;1197:178–183.
13. Gurer A, Ozdogan M, Gomceli I, et al. Hyperbaric oxygenation attenuates renal ischemia-reperfusion injury in rats. *Transplant Proc* 2006;38:3337–3340.
14. Zamboni WA, Roth AC, Russell RC, Graham B, Suchy H, Kucan JO. Morphologic analysis of the microcirculation during reperfusion of ischemic skeletal muscle and the effect of hyperbaric oxygen. *Plast Reconstr Surg* 1993;91:1110–1123.
15. Baynosa RC, Naig AL, Murphy PS, et al. The effect of hyperbaric oxygen on nitric oxide synthase activity and expression in ischemia-reperfusion injury. *J Surg Res* 2013;183:355–361.
16. Nylander G, Lewis D, Nordstrom H, Larsson J. Reduction of postischemic edema with hyperbaric oxygen. *Plast Reconstr Surg* 1985;76:596–603.
17. Reinisch JF. Pathophysiology of skin flap circulation. *Plast Reconstr Surg* 1974;54:585.
18. Kivisaari J, Niinikoski J. Effects of hyperbaric oxygen and prolonged hypoxia on the healing of open wounds. *Acta Chir Scand* 1975;141:14–19.
19. Korn HN, Wheeler ES, Miller TA. Effect of hyperbaric oxygen on second degree burn wound healing. *Arch Surg* 1977;122:732–737.
20. Shulman AG, Krohn HL. Influence of hyperbaric oxygen and multiple skin allografts on the healing of skin wounds. *Surgery* 1967;62:1051–1058.
21. Calderwood JW. The effect of hyperbaric oxygen in the transplantation of epiphyseal growth cartilage in the rabbit. *J Bone Joint Surg* 1974;56B:735–739.
22. Renner G, McClane SD, Early E, Bell P, Shaw B. Enhancement of auricular composite graft survival with hyperbaric oxygen therapy. *Arch Facial Plast Surg* 2002;4:102–104.
23. Lewis D, Goldztein H, Deschler D. Use of hyperbaric oxygen to enhance auricular composite graft survival in the rabbit model. *Arch Facial Plast Surg* 2006;8:310–313.
24. Zhang F, Cheng C, Gerlach T, Kim DY, Lineaweaver WC, Buncke HJ. Effect of hyperbaric oxygen on survival of the composite ear graft in rats. *Ann Plast Surg* 1998;41:530–534.
25. Li EN, Menon NG, Rodriguez ED, et al. The effect of hyperbaric oxygen therapy on composite graft survival. *Ann Plast Surg* 2004;53:141–145.
26. Zamboni WA, Baynosa RC. Compromised grafts and flaps. In: Neuman TS, Thom SR, eds. *Physiology and Medicine of Hyperbaric Oxygen Therapy*. Philadelphia, PA: Elsevier, Inc., 2008:375.
27. Nemiroff PM, Merwin GE, Brant T, Cassisi NJ. Effects of hyperbaric oxygen and irradiation on experimental flaps in rats. *Otolaryngol Head Neck Surg* 1985;93:485–491.
28. Arturson GG, Khanna NN. The effects of hyperbaric oxygen, dimethyl sulfoxide and complamin on survival of experimental skin flaps. *Scand J Plast Reconstr Surg* 1970;4:8–10.
29. Pellitteri PK, Kennedy TL, Youn BA. The influence of intensive hyperbaric oxygen therapy on skin flap survival in a swine model. *Arch Otolaryngol Head Neck Surg* 1992;118:1050–1054.
30. Champion WM, McSherry CK, Goulian D. Effect of hyperbaric oxygen on survival of pedicled skin flaps. *J Surg Res* 1967;7:583–586.
31. Jurell G, Kaijser L. The influence of varying pressure and duration of treatment with hyperbaric oxygen on the survival of skin flaps: an experimental study. *Scand J Plast Reconstr Surg* 1973;7:25–28.
32. Lozano DD, Stephenson LL, Zamboni WA. Effect of hyperbaric oxygen and medicinal leeching on survival of axial skin flaps subjected to total venous occlusion. *Plast Reconstr Surg* 1999;104:1029–1032.
33. Ulkur E, Yuksel F, Acikel C, Celikoz B. Effect of hyperbaric oxygen on pedicle flaps with compromised circulation. *Microsurg* 2002;22:16–20.
34. Perrins DJD, Cantab MB. Influence of hyperbaric oxygen on the survival of split skin grafts. *Lancet* 1967;1:868–871.
35. Nichter LS, Morwood DT, Williams GS, Spence RJ. Expanding the limits of composite grafting: a case report of successful nose replantation assisted by hyperbaric oxygen therapy. *Plast Reconstr Surg* 1991;87:337–340.
36. Rapley JH, Lawrence WT, Witt PD. Composite grafting and hyperbaric oxygen therapy in pediatric nasal tip reconstruction after avulsive dogbite injury. *Ann Plast Surg* 2001;46:434–438.
37. Shimada T, Yakeshita Y, Murohara T, et al. Angiogenesis and vasculogenesis are impaired in the precocious-aging klotho mouse. *Circulation* 2004;110:1148–1155.
38. Bowersox JC, Strauss MB, Hart GB. Clinical experience with hyperbaric oxygen therapy in salvage of ischemic skin flaps and grafts. *J Hyperbaric Med* 1986;1:141–149.
39. Waterhouse MA, Zamboni WA, Brown RE, Russell RC. The use of HBO in compromised free tissue transfer and replantation, a clinical review. *Undersea Hyperbaric Med* 1993;20(Suppl):64.
40. Roje Z, Roje Z, Eterovic D, et al. Influence of adjuvant hyperbaric oxygen therapy on short-term complications during surgical reconstruction of upper and lower extremity war injuries: retrospective cohort study. *Croat Med J* 2008;49:224–232.
41. Larson JV, Steensma EA, Flikkema RM, Norman EM. The application of hyperbaric oxygen therapy in the management of compromised flaps. *Undersea Hyperb Med* 2013;40:499–504.
42. Skeik N, Porten BR, Isaacson E, et al. Hyperbaric oxygen treatment outcome for different indications from a single center. *Ann Vasc Surg* 2015;29:206–214.

43. Qing Y, Cen Y, Chen J, Ke S. Reconstruction of a large through-and-through defect of the nasal tip using a modified auricular composite graft. *J Craniofac Surg* 2015;26:382–383.
44. Fredman R, Wise I, Friedman T, Heller L, Kami T. Skin-sparing mastectomy flap ischemia salvage using urgent hyperbaric chamber oxygen therapy: a case report. *Undersea Hyperb Med* 2014;41:145–147.
45. Copeland-Halperin LR, Bruce SB, Mesbahi AN. Hyperbaric oxygen following bilateral skin-sparing mastectomies: a case report. *Plast Reconstr Surg Glob Open* 2016;4:e680.
46. Zhou YY, Liu W, Yang YJ, Lu GD. Use of hyperbaric oxygen on flaps and grafts in China: analysis of studies in the past 20 years. *Undersea Hyperb Med* 2014;41:209–216.
47. Tibbles PM, Edelsberg JS. Hyperbaric-oxygen therapy. *N Engl J Med* 1996;334:1642–1648.
48. Marx RE. Radiation injury to tissue. In: Kindwall EP, ed. *Hyperbaric Medicine Practice*. Flagstaff, AZ: Best, 1994:447–503.
49. Baynosa RC, Zamboni WA. The effect of hyperbaric oxygen on compromised grafts and flaps. *Undersea Hyperb Med* 2012;39:857–865.
50. Dooley J, King G, Slade B. Establishment of reference pressure of transcutaneous oxygen for comparative evaluation of problem wounds. *Undersea Hyperb Med* 1997;24:235–244.

Abbreviations and Acronyms

ATA	= atmospheres absolute
HBO	= hyperbaric oxygen
IR	= ischemia–reperfusion
NOS	= nitric oxide synthase
TCOM	= transcutaneous oximetry
VEGF	= vascular endothelial growth factor